

## HEMATOLOGICAL AND BLOOD-BIOCHEMISTRY PARAMETERS OF GUINEA FOWLS IN EARLY STAGE OF NITROSODIETHYLAMINE-INDUCED HEPATOCARCINOGENESIS

**Branimir Nikolov<sup>1</sup>, Vasil Manov<sup>1</sup>, Roman Pepovich<sup>1</sup>, Tanzhu Mehmedov<sup>1</sup>, Kalin Hristov<sup>1</sup>, Krasimira Genova<sup>1</sup>, Elena Nikolova<sup>2</sup>, Reneta Petrova<sup>2</sup>, Ani Georgieva<sup>3</sup>, Anton Kril<sup>3</sup>**

<sup>1</sup>*University of Forestry, Faculty of Veterinary Medicine, Sofia, Bulgaria*

<sup>2</sup>*National Diagnostic Research Veterinary Medical Institute, Sofia, Bulgaria*

<sup>3</sup>*Institute of Experimental Morphology, Pathology and Anthropology with Museum, Bulgarian Academy of Sciences, Sofia, Bulgaria*

*E-mail: br\_nikolov@abv.bg*

### ABSTRACT

*In ovo* models (avian embryos) are a novel alternative to laboratory animals used in the experimental cancer research. In the present study, the preneoplastic liver lesions induced by N-nitrosodiethylamine in guinea fowls were examined by histopathological methods. The alterations of some hematological and biochemical parameters were examined in guinea fowls hatched from carcinogen-inoculated eggs. Histopathology confirmed the presence of basophilic and eosinophilic foci of altered hepatocytes, strongly resembling the morphology of the preneoplastic lesions previously found in other avian species and laboratory rodents treated with the same carcinogen, as well as in humans with hepatocellular carcinomas. In addition to the focal hepatic lesions, pronounced hyperplasia of cholangiocytes and *spongiosis hepatis* were also detected in treated guinea fowls. The established alterations of hematological and biochemical parameters included thrombocytopenia and an increase of the levels of major liver enzymes and were related to the hepatocarcinogenesis. In addition, changes in the leukogram (leukocytosis, lymphocytosis and granulocytosis), as well as hypoproteinemia, hypoalbuminemia and hypoglycemia were observed.

**Key words:** *in ovo* tests, guinea fowl, hepatocarcinogenesis, N-nitrosodiethylamine, hematological and biochemical parameters.

### Introduction

Animal experimentation is still one of the major approaches used for safety assessment of chemical substances intended for human or animal use. (Iatropoulos et al., 2001; Pitot, 2007, Marone et al. 2014). With the adoption and implementation of the new Directive 2010/63 / EU of the European Parliament and the Council of EU on the protection of animals used for scientific purposes, studies aimed at the development of novel alternative models and methods have been gaining an increasing importance. A number of *in vitro* and *in silico* models and methods for evaluation of the carcinogenic potential of the chemical substances have been developed (Anadon et al., 2014). Some of them are now included in the test panels used for chemical risk assessment. The importance of avian embryos as an alternative to the laboratory animals for studies on various pathological processes, including carcinogenesis, is rising steadily (Williams et al., 2014). Moreover, *in ovo* tests for mutagenicity and carcinogenicity (using chicken, turkey or quail embryos) have been proposed and some of them have been subjected to validation studies (Enzmann and Brunnemann, 1997, Williams et al., 2011, Enzmann et al., 2013).

The aims of the present study are to investigate the nature of the liver lesions and some hematological and biochemical parameters in early stage of N-nitrosodiethylamine-induced hepatocarcinogenesis in guinea fowl.

## **Materials and methods**

### **Avian embryos**

Fertilized guinea fowl (*Numida meleagris*) eggs were obtained from birds of diseases-free flock in the animal-housing facilities of IEMPAM-BAS, Sofia, Bulgaria.

### **Chemical carcinogen and *in ovo* treatment**

N-nitrosodiethylamine (NDEA, CAS № 55-18-5; Sigma-Aldrich) was diluted with sterile double distilled water. The *in ovo* carcinogen-treatment was performed as previously described (Enzmann and Brunnemann, 1997, Enzmann et al., 2013). Briefly, NDEA was administered as single dose of 0.2 mg/per egg, with an injection volume of 0.1 ml. Control eggs were injected with an equal volume of the vehicle. The eggs were inoculated during the first hours of incubation. After sterilization of the injection site with 70% ethanol, the shell was pierced at the pointed end of the egg, using a needle. Test substance was inoculated into the egg albumen and the opening was sealed with paraffin. The eggs were incubated in an automatic rotating incubator and at the end of the incubation period were transferred to a hatcher.

### **Experimental birds**

Twelve guinea fowls hatched from the treated and control eggs were used in the experiments and each group consisted of six birds. Standard fodder mixtures were used for feeding. Food and water were available *ad libitum*. The experimental birds were exsanguinated at the 45th day after hatching. All experiments were conducted in accordance to the ethical standards of the institutional and national guidelines for care and use of laboratory animals.

### **Histopathology**

Liver samples were taken from the control and treated birds and immediately fixed in 10% buffered formalin for subsequent histopathological examination. Fixed tissues were routinely dehydrated, paraffin embedded, sectioned at 5 µm and stained with hematoxylin and eosin (H&E). Histopathological lesions were identified and documented with microscope Leica DM 5000 B.

### **Hematology**

Venous blood was taken from the wing vein of the treated and control birds 30 days after hatching. Haematological parameters (WBC, 10<sup>9</sup>/L; LYM, 10<sup>9</sup>/L; MID, 10<sup>9</sup>/L; GRA, 10<sup>9</sup>/L; HGB, g/L; RBC, 10<sup>12</sup>/L; HCT,%; PLT, 10<sup>9</sup>/L) were measured in whole blood by Veterinary automatic hematology analyzer Hema Screen 18 LIHD 170, (Hospitex diagnostics – Italy).

### **Biochemistry**

Biochemical parameters (total protein, g/L; albumin, g/L; alanine aminotransferase (ALAT), U/L; aspartate aminotransferase (ASAT), U/L; and gama-glutamyl transferase (GGT), U/L) were measured in the blood serum by a semi-automatic biochemical analyzer Screen Master LIHD 113, (Hospitex diagnostics – Italy) and reagent kits for biochemical analyses (Human – Germany).

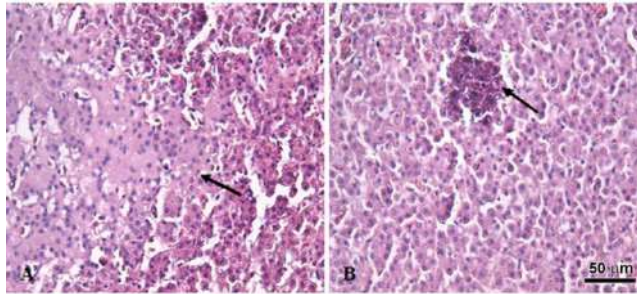
### **Statistical analysis**

All data are presented as mean values ± standard deviation. The statistical significance of the differences between the control and treatment groups was evaluated by SPSS 16.0 software package

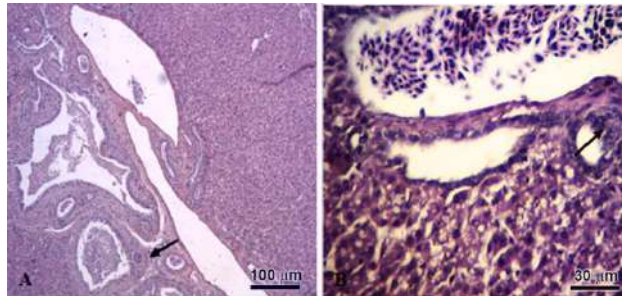
(IBM Corporation) using one-way analysis of variance (ANOVA). Values of \* $p < 0.05$ , \*\* $p < 0.01$  and \*\*\* $p < 0.001$  were considered statistically significant.

## Results

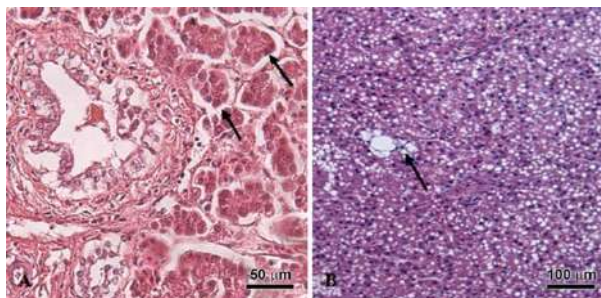
The histopathological examination shows presence of pre-neoplastic liver lesions in all birds treated with N-nitrosodiethylamine in the early stages of their embryonic development. These lesions were classified as foci of altered hepatocytes with an eosinophilic and basophilic phenotype (Fig. 1). In addition, prominent hyperplasia of cholangiocytes has been detected in liver samples from all experimental birds (Fig. 2). Pseudo-acinar structures and *spongiosis hepatis* (Fig. 3) were occasionally found in separate samples.



**Figure 1: Light microscopy of FAHs in liver samples from guinea fowls, treated with NDEA.**  
A) Focus of eosinophilic altered hepatocytes, H&E; B) Focus of basophilic altered hepatocytes H&E.

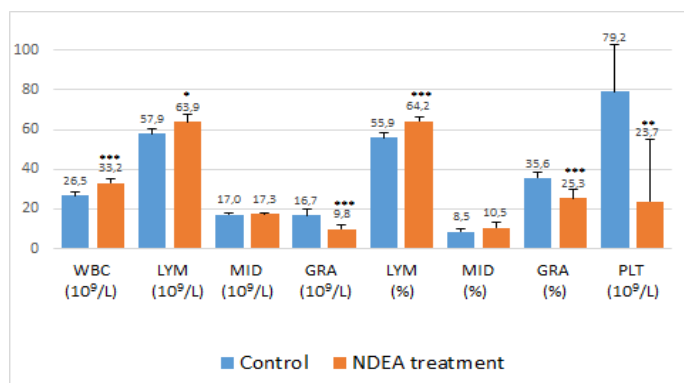


**Figure 2: Light microscopy of altered bile ductules in liver samples from guinea fowls, treated with NDEA**  
A) Hyperplasia of cholangiocytes, H&E; B) Pseudopapillary hyperplasia of cholangiocytes, H&E.



**Figure 3: Light microscopy of pseudo-acinar structures (A) and *spongiosis hepatis* (B) (arrows) in liver samples from guinea fowls, treated with NDEA, H&E.**

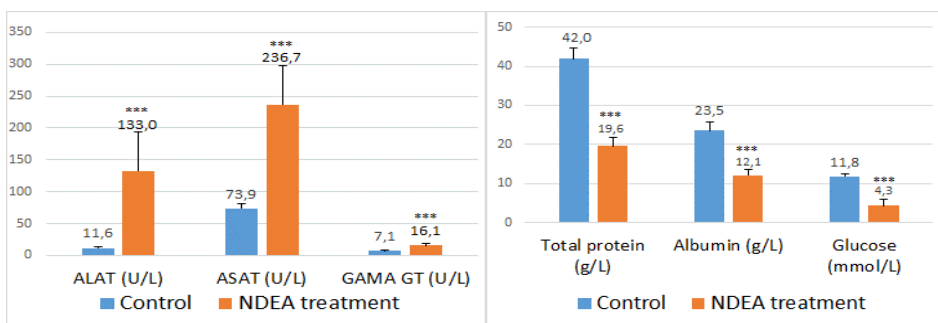
Hematological investigations of white blood cells count revealed a significant ( $p \leq 0.001$ ) leukocytosis with lymphocytosis, accompanied by prominent neutropenia and thrombocytopenia (Fig. 4). The erythrocytes count of the birds from experimental group ( $2.24 \pm 0.05$ ) where also significantly lower ( $p \leq 0.001$ ) compared to red blood cells number in guinea fowls from the control group ( $3.18 \pm 0.17$ ). A decrease in hemoglobin and hematocrit has been observed, however values did not reached statistical significance.



Mean  $\pm$  SE \*  $p \leq 0.05$ ; \*\*  $p \leq 0.01$ ; \*\*\*  $p \leq 0.001$

Figure 4: White blood cell and thrombocyte count of treated and control guinea fowls.

The results of the biochemical studies have shown statistically significant increase of the levels of the main liver enzymes - ALAT and ASAT, and a double increase of GGT activity ( $p \leq 0.001$ ) (Fig. 5). In addition, prominent hypoproteinemia, hypoalbuminemia and hypoglycemia ( $p \leq 0.001$ ) have been observed (Fig. 5).



Mean  $\pm$  SE \*  $p \leq 0.05$ ; \*\*  $p \leq 0.01$ ; \*\*\*  $p \leq 0.001$

Figure 5: Blood serum biochemical profile of treated and control guinea fowls.

## Discussion

Histopathology of the livers of 45 days-old guinea fowl, treated with NDEA in the beginning of their embryo development, has shown the presence of preneoplastic lesions, classified as foci of altered hepatocytes with eosinophilic and basophilic phenotype. Foci of altered hepatocytes (FAHs) represent the most prevalent form of hepatic preneoplasia observed in animals for a long time and more recently identified in human chronic liver diseases associated with, or predisposing to,

hepatocellular carcinomas (Bannasch et al., 2003, Su and Bannasch, 2003). A prominent hyperplasia of cholangiocytes was also detected in the liver sections from all experimental birds. In addition, formation of pseudo-acinar structures and *spongiosis hepatis* were occasionally found in some samples from experimental birds. Similar changes in turkey, quail and guinea fowl embryos exposed *in ovo* to N-nitrosodimethylamine, N-nitrosodiethylamine and N-nitrosomorpholine, have been previously described (Enzmann et al., 1992; 1995; 1996; Williams et al., 2011, Nikolov et al., 2015). The development of preneoplastic FAHs has been also found in the liver of chicken embryos after treatment with organic (Georgieva et al., 2011) and inorganic carcinogenic chemicals (Kril et al., 2011), as well as after experimental infection with avian oncogenic retroviruses (Georgieva et al., 2011). In fact, FAHs have been found in all animal species studied, including primates (Bannasch et al., 1997). The striking morphological and biochemical similarities in the cells of FAHs detected in experimental and human hepatocarcinogenesis favors the extrapolation of data obtained in experimental animals to humans (Williams et al., 2014).

In the present study, the liver lesions in guinea fowls hatched from NDEA-inoculated eggs were examined in order to determine whether the preneoplastic lesions observed in the guinea fowl embryos will progress to neoplasia during a 45-days post-hatching period. Our previous results have revealed the presence of hepatocellular carcinoma cells, with clearly expressed signs of malignancy in livers samples from 18-weeks old chickens, exposed *in ovo* to the same carcinogen. The results presented here indicate that the 45-days period was not sufficient for the development of neoplastic alterations in the livers of the experimental birds.

The biochemical profile of the treated and the control birds revealed marked increase of the levels of main liver enzymes (ALAT, ASAT and GGT). Aspartate aminotransferase, alanine aminotransferase and gamma-glutamyl transferase are known as a sensitive and reliable indicators for liver failure in other bird species (Harisson et al., 1994). The increased ALAT activity is considered more specific marker for liver damage than the ASAT levels due to the higher concentration of this enzyme in the liver and its longer half-life in blood plasma. In addition, hypoproteinaemia, hypoalbuminemia and hypoglycaemia have been detected. The hematological parameters have shown leukocytosis with lymphocytosis, accompanied by significant neutropenia, thrombocytopenia and erythropenia. The latter results correspond well with the histopathological findings in the livers of the experimental birds, namely the significant alterations of hepatocyte morphology and confirm the marked hyperplasia of the cholangiocytes.

## Conclusion

*In ovo* application of N-nitrosodiethylamine includes preneoplastic and hyperplastic lesions in the livers of guinea fowl hatched from inoculated eggs.

The results of the hematological and biochemical studies complement well the observed morphological changes in the liver.

The established hypoalbuminemia, relative anemia and hypoglycemia show not only changes in the main liver functions, but also represent an essential part of the paraneoplastic syndrome, accompanying hepatocarcinogenesis.

## References

1. Iatropoulos, M. J., A. M. Jeffrey, H. G. Enzmann, E. von Keutz, G. Schlueter, G. M. Williams. (2001). *Assessment of chronic toxicity and carcinogenicity in an accelerated cancer bioassay in rats*

- of moxifloxacin, a quinolone antibiotic.* Exp Toxicol Pathol, 53, 345–357.
2. Pitot, H. C. (2007). *Adventures in hepatocarcinogenesis.* Annual Review of Pathology, 2, 1–29.
  3. Marone, P., Hall, W., Hayes, A. (2014). *Reassessing the two-year rodent carcinogenicity bioassay: a review of the applicability to human risk and current perspectives.* Regul Toxicol Pharm, 68, 108–118.
  4. Anadón, A., Martínez, M., Castellano, V., Martínez-Larrañaga, M. (2014). *The role of in vitro methods as alternatives to animals in toxicity testing.* Expert Opin Drug Met, 10, 67–79.
  5. Pitot, H. (2007). *Adventures in hepatocarcinogenesis.* Annu Rev Pathol, 2, 1–29.
  6. Williams, G., Iatropoulos, H. Enzmann, U. Deschl. (2014). *Carcinogenicity of chemicals: assessment and human extrapolation.* In: Hayes' principles and methods of toxicology, Hayes W and Claire L. Kruger C. eds., CRC Press, 1251–1305.
  7. Enzmann, H. G., K. D. Brunnemann. (1997). *The in ovo carcinogenicity assay (IOCA): A review of an experimental approach for research on carcinogenesis and carcinogenicity testing.* Frontiers in Bioscience, 2, 30–39.
  8. Williams, G. M., K. D. Brunnemann, M. J. Iatraopoulos, D. J. Smart, H. G. Enzmann. (2011). *Production of liver preneoplasia & gallbladder agenesis in turkey fetuses administered diethylnitrosamine.* Arch Toxicol, 85, 681–687.
  9. Enzmann, H., Brunnemann, K., Iatropoulos, M., Shpyleva, S., Lukyanova, N., Todor, Williams, G. (2013). *Inter-laboratory comparison of turkey in ovo carcinogenicity assessment (IOCA) of hepatocarcinogens.* Experimental and Toxicologic Pathology, 65(6), 729–735.
  10. Enzmannp, H., K. D. Brunnemann, M. Iatropoulos and G. M. Williams. (1996). *Induction of hyperplastic lesions in embryonic quail liver in ovo.* Proc. AACR Annual Meeting, 777, 20–24.
  11. Bannasch, P., Haertel, T., Su, Q. (2003). *Significance of Hepatic Preneoplasia in Risk Identification and Early Detection of Neoplasia.* Toxicol Pathol, 31, 134–139.
  12. Su, Q, Bannasch, P. (2003). *Relevance of hepatic preneoplasia for human hepatocarcinogenesis.* Toxicol Pathol, 31, 126–133.
  13. Enzmann, H. G., B. Kaliner. Watta-Gebert & E. Löser. (1992). *Foci of altered hepatocytes induced in embryonal turkey liver.* Carcinogenesis, 13, 943–946.
  14. Enzmann, H. G., C. Kuhlem, G. Kaliner, E. Löser, P. Bannasch. (1995). *Rapid induction of preneoplastic liver foci in embryonal turkey liver by diethylnitrosamine.* Toxicologic pathology, 23(5), 560–569.
  15. Williams, G. M., K. D. Brunnemann, M. J. Iatraopoulos, D. J. Smart, H. G. Enzmann. (2011). *Production of liver preneoplasia & gallbladder agenesis in turkey fetuses administered diethylnitrosamine.* Arch Toxicol, 85, 681–687.
  16. Nikolov, B., V. Manov, R. Pepovich, T. Mehmedov, K. Hristov, K. Genova, E. Nikolova, R. Petrova, A. Georgieva, A. Kril. (2015). *Hematological and biochemical parameters during the early stages of n-nitrosodiethylamineinduced hepatocarcinogenesis in turkeys.* Scientific works. Series c. Veterinary medicine, Vol. LXI (1), 122–127.
  17. Georgieva, A., I. Ivanov, A. Kril, G. Radoslavov. (2013). *Novel models of avian leucosis virus induced carcinogenesis.* Comptes rendus de l'Acad'e'mie bulgare des Sciences, 66(1), 45–52.
  18. Kril, A., A. Georgieva, P. Dimitrov, I. Ivanov. (2011). *In ovo effects of cadmium chloride and lead nitrate.* Comptes rendus de l'Acad'e'mie bulgare des Sciences, 64(8), 1199–1204.
  19. Georgieva, A., A. Kril, I. Ivanov. (2011). *In ovo study on the embryotoxic, mutagenic and carcinogenic potential of the ethylene bisdithiocarbamate fungicide mancozeb.* Comptes rendus de l'acad'e'mie bulgare des sciences, 64(8), 1205–1212.
  20. Harisson L. R., G. J. Harisson, W. R. Branson. (1994). *Avian Medicine: principles & application.* 523–525/657–658.
  21. Bannasch, P., Jahn, U., Hacker, H., Su, Q., Hoffmann, W., Pichlmayr, R., Otto, G. (1997). *Focal hepatic glycogenosis: a putative preneoplastic lesion associated with neoplasia and cirrhosis in explanted human livers.* Int J Oncol, 10, 261–268.