

LEVELS OF LEAD IN TISSUES OF MALLARDS (*Anas platyrhynchos*, L) EXPERIMENTALLY EXPOSED TO SHOT PELLETS

**Petar Stamberov¹, Toni Todorov¹, Sofiya Ivanova², Marin Alexandrov³,
Kalin Hristov¹, Tandzhu Mehmedov¹, Iliyan Manev¹, Ella Taneva¹**

¹*University of Forestry, Faculty of Veterinary Medicine, Sofia, Bulgaria*

²*National Diagnostic and Research Veterinary Medical Institute „Prof. Dr. Georgi Pavlov”,
Sofia, Bulgaria*

³*Institute of Experimental Morphology, Pathology and Anthropology with Museum, Bulgarian
Academy of Sciences, Sofia, Bulgaria*

Email: bestvet_pepi@abv.bg

ABSTRACT

The paper presents for determination of lead in the liver, kidney, breast muscles and humerus of mallards (*Anas platyrhynchos*, L), treated orally with lead shot pellets. The results obtained show significant elevation tissue concentrations of lead in relation to the control values. The highest values were established in the humerus, followed by the kidneys, liver and breast muscles.

Key words: mallards, lead, hunting pellets, tissues, toxicological analysis.

Introduction

Waterfowl are exposed to the toxic effects from lead due to the ingestion of lead pellets from the bottom of the natural reservoirs in areas with intense hunting activities. The lead pellets used in hunting activities contaminate wetlands worldwide as their density in many places in the upper 20 cm of sediment is over 100 pellets /m² (Mateo, 2009). Lead acts at a molecular level and may lead to a number of toxic effects which have been well described in waterfowl (Beyer et al., 1988; Pain et al., 2009).

According to Sanderson and Bellrose (1986), the ingestion of 1 or 2 pellets can be fatal, accompanied by morphological and functional changes in the birds and a loss of 30–50% of their normal body weight. Lead concentrations are highest after direct absorption into the bloodstream, after which the lead accumulates in the kidneys and liver for days or months, and if the process becomes chronic, it is then deposited in the bones with the possibility of a lifetime exposure (De Francisco et al., 2003). The monitoring of the poisoning in waterfowl is difficult due to their inaccessible habitat, mobility and, last but not least, the fact that the poisoned birds become an easy prey for predators and vultures. Making a definitive diagnosis of the poisoning requires specialized laboratory analyzes.

The purpose of the current study is the quantification of lead in liver, kidney, breast muscles and humerus of mallards, experimentally treated with lead pellets in various doses.

Material and methods

Sixteen clinically healthy mallards (*Anas platyrhynchos*) aged between 9 and 12 months were evenly divided (n = 4) in four groups and housed in separate aviaries. After a 7-day adaptation period the birds were treated orally once with lead pellets #3 (medium weight 0.267 g), as follows: I group –

3 lead pellets; II group – 2 lead pellets; III group – 1 lead pellet. The ducks from the IV group were used as a negative control.¹

The survey was conducted between 23.02.2016-28.03.2016, in the Laboratory of Ecology and technical tests "Akvateratest" Sofia. The samples were analyzed by the methods of inductively coupled plasma spectrometry mentioned above. The spectrometers Varian Vista-MPX CCD Simultaneous ICP OES, Varian Australia, and Plasma Quant MS S-NR 105000-AQ032, Analytik Jena A G, Germany were used.

The analysis and statistical processing of the data were performed by the computer program SPSS 19.0. The data is expressed as mean plus standard error. In this study the assessment is made with guaranteed probability 0.95 (significance level $\alpha = 0,05$), where $p < 0,05$ was adopted as the lowest level of statistical reliability.

Results

During the experiment, the severity of clinical signs and pathological lesions correlated with the levels of lead in soft tissues and bones, and were proportional to the dosage of the applied lead pellets in the mallards tested.

One of the earliest clinical signs to appear was the reduced food intake. Either the appetite of the affected bird dropped completely or the food consumption decreased to a level below the minimum nutritional requirements which lead to a progressive loss of weight. The characteristic bright greenish diarrhetic feces occur as early as the seventh day after the mallards were dosed with factory lead pellets #3. A few days before their death a high degree of cachexia, photophobias, vocal changes, loss of appetite and completely altered motor function with paralysis of the limbs were registered, along with body weight loss between 25 and 50% in the experimental mallards.

Following the death of the mallards, the main macroscopic findings included cachexia, loss of body fat, bright green coloration in the area of the cloaca, slightly enlarged, yellowish colored liver and enlarged and filled with content gallbladder. The mucosa of the muscular stomach was greenish-gray with the presence of ulcerative lesions where the lead pellets could be found. In the experimental animals of I and II group the weight of the lead pellets had dropped averagely by 25% from the initially measured. The most typically expressed pathomorphological changes are detected in the liver and kidneys where acidophilus intranuclear inclusions in hepatocytes and proximal renal tubular cells are observed.

From the toxicological analysis is observed repeatedly increased content of lead in the liver, kidney and the humerus in experimentally treated mallard ducks, compared with the control group (Table 1).

¹ This study was approved by the Commission for animal welfare at the Faculty of Veterinary Medicine, University of Forestry - Sofia (Permit Number: № 80, valid until 2018 for educating students and conducting scientific research in veterinary medicine) and is conducted in compliance with EU and the national legislation.

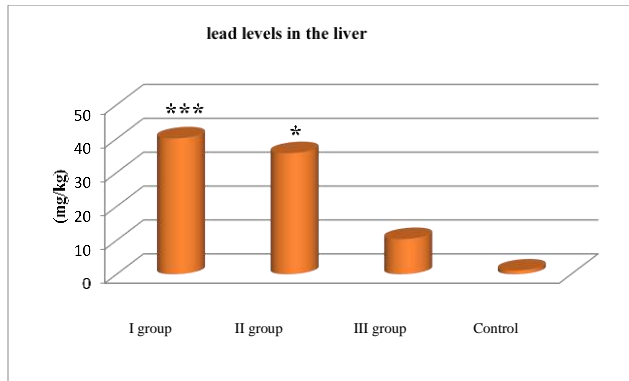
Table 1: Lead content in biological material from the liver, kidney, breast muscle and humerus in mallards after experimental application of lead ammunition.

Material Group	Liver mg/kg	Kidney mg/kg	Breast muscle mg/kg	Humerus mg/kg
I n = 4	40.100 ± 1.597***	65.203 ± 7.067***	2.0575 ± 0.301**	86.695 ± 10.801***
II n = 4	35.725 ± 12.874*	53.607 ± 8.741**	1.450 ± 0.144*	68.907 ± 11.657**
III n = 4	10.375 ± 6.201	7.862 ± 2.780	0.650 ± 0.150	59.475 ± 13.169**
IV Control n = 4	1.097 ± 0.184	3.200 ± 0.286	0.500 ± 0.032	1.000 ± 0.161

Statistically significant difference compared to the control group:

* $p < 0.05$; ** $p < 0.01$; *** $p < 0.001$

There were statistically significant differences respectively, $p < 0,001$, for the content of lead in the liver of the mallards from the first experimental group (three pcs. of lead pellets # 3) compared to the control group, and $p < 0,05$ between the second test group (two pcs. of lead pellets # 3) compared to the control group. The results of the comparative analysis of lead levels in the liver, between the mallards in the third test group and the control group, did not show statistically significant differences, but graphically and quantitatively reflected significant difference of tenfold elevated level in the test subjects treated with one lead pellet # 3 (Fig. 1).



* Statistically significant difference compared to the control group: $p < 0,05$.

*** Statistically significant difference compared to the control group: $p < 0,001$.

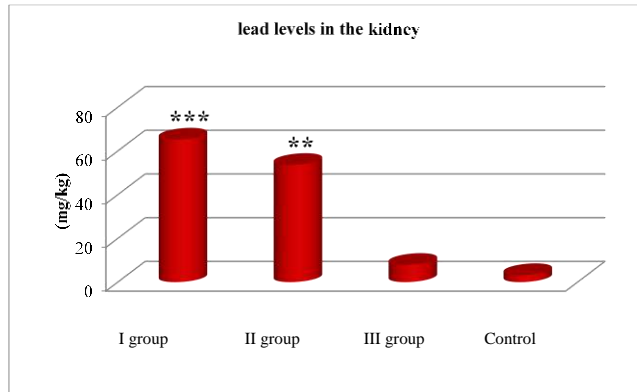
Figure 1: Lead concentrations in the liver of mallards

Regarding the content of lead in the kidney, the comparative quantitative analysis was similar to the data reported in the liver.

Again, we found absolute statistical reliability between the individuals treated with the highest dose in the first test group and the control group (Fig. 2).

In the mallards from II group the result confirmed that the administered dose of two lead pellets # 3 with a total mass of over 0,5 g resulted in an increase of the lead levels in the kidney over twenty times compared to the reported values in the control group (Fig. 2).

In the least dosed experimental mallards from the third test group, there are no statistically significant differences in comparison to the control group (Fig. 2).



** Statistically significant difference compared to the control group: where $p < 0,01$.
 *** Statistically significant difference compared to the control group: where $p < 0,001$.

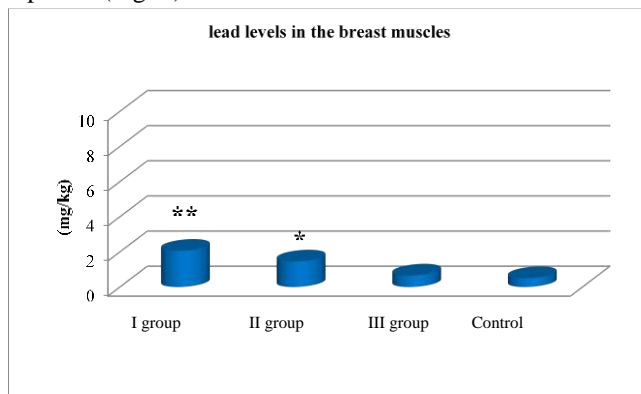
Figure 2: Lead concentrations in the kidney of mallards

Unlike the highly elevated levels in the liver and kidneys, the lead concentration in the breast muscles showed low concentrations of lead, however only the control group only meets the regulatory standards of 0.1–0.5 mg/kg (Fig. 3).

The obtained results for the lead concentration in the breast muscle of the mallards from the first test group were four times higher than those of the control group, corresponding to a statistically significant difference of $p < 0,05$ (Fig. 3).

In the ducks from the second test group the levels of lead in the breast muscle were increased three times compared to the control group, and a statistically significant difference of $p < 0,05$ (Fig. 3).

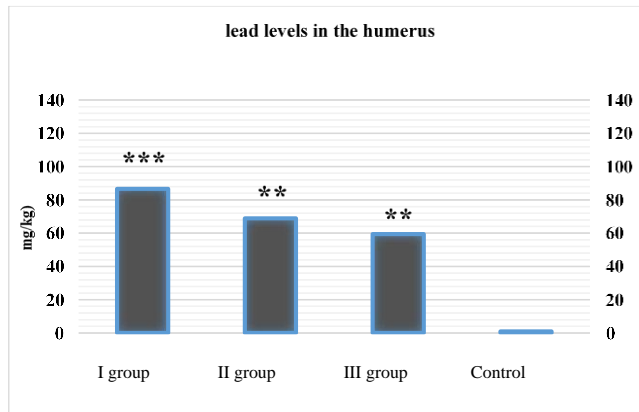
Regarding the lead concentration in the breast muscles of the least exposed mallards in the third test group (one lead pellet # 3) compared to the control group, slightly elevated levels of 0.65 ± 0.15 mg/kg were reported (Fig. 3).



* Statistically significant difference compared to the control group: where $p < 0,05$.
 ** Statistically significant difference compared to the control group: where $p < 0,01$.

Figure 3: Lead concentrations in the breast muscles of mallards

The analysis of the humerus of the experimental mallards, clearly showed statistically significant differences in all three experimental groups in terms of lead concentration, compared to the individuals in the control group (Fig. 4).



** Statistically significant difference compared to the control group: where $p < 0,01$.

*** Statistically significant difference compared to the control group: where $p < 0,001$

Figure 4: Lead concentration in the humerus of mallards

The most experimentally exposed to lead individuals from the first group show lead concentration in the humerus of 86.695 ± 10.801 mg/kg, i.e. between 50–120 times more than those from the control group, which after a statistical processing of the data is expressed as an absolute statistical reliability ($p < 0,001$).

In the mallards in the second test group (treated with two lead pellets # 3) average levels of 68.907 ± 11.657 mg/kg ($p < 0,01$) in the humerus or about 40–100 times higher than in those in the control group were reported (Fig. 4).

Unlike the other quantitative analyzes of the rest of the target tissues, in which in the third test group there were relatively low concentrations, the lead concentration in the humerus is very high, with the presence of a wide individual range and an average of 59.475 ± 13.169 mg/kg ($p < 0,01$), compared to the low concentrations reported in the control group (Fig. 4).

Discussion

The obtained values by us above 40–50 mg/kg for lead content in the liver and between 60–70 mg/kg in the kidneys in individuals from the first and second experimental groups, indicate signs of acute poisoning, accompanied by serious tissue damages. The higher content of lead in the kidneys compared to the liver described by other authors as well (Di Giulio and Scanlon, 1984; Jeng et al., 1997; Szymczyk and Zalewski, 2003; Hutařová et al., 2015), could mean that the kidneys are damaged irreversibly and cannot excrete the cumulating lead. Unlike the third test group whose lead content is in the range of less than 7 mg/kg for the kidneys and 10 mg/kg for the liver, whereas such levels are characteristic of a subclinical effects with possible cumulative effect and chronification. In some of the individuals it a partial recovery could be possible because the liver and kidneys, along with the blood flow and cardiac tissue are so called "fast-exchanging systems" and a small amount of lead could be absorbed and excreted (Friend, 1987; Szymczyk and Zalewski, 2003).

The lead content in the breast muscles is a rather secondary indicator for the lead concentration in case of an oral exposure unlike the liver and kidneys (Jordan and Bellrose 1951; Mateo et al., 2001; Binkowski et al., 2013 b). In our study, the lead concentration is low compared to the other target organs. Nevertheless, the obtained elevated levels in the first (2.05 ± 0.301 mg/kg) and second (1.4500 ± 0.144 mg / kg) experimental groups contrasted greatly with of the individuals from the control group, whose levels did not exceed 0.5 mg/kg. The least treated (with one lead pellet) individuals of the third test group showed low lead concentrations in the breast muscles of 0.65 ± 0.150 mg/kg, without statistical significance compared to the control group, which is consistent with the results published by other authors (Hutařová et al., 2015).

The results obtained from analyzing the levels of lead in the humerus are indicative of a severe clinical form of poisoning with a fatal outcome or with the possibility of long-term (lifetime) exposure and chronification of the process (Kalisińska et al., 2003; Pain et al., 2009; Hutařová et al., 2015). The high lead concentration measured in the bones of all three experimental groups contrasted sharply with the low levels of the control group, and was in accordance with the severity of the administered dose (Del Bono and Braca, 1974; Kamil et al., 2012). The bone tissue is the last link in which the lead is deposited after active transport by the hematopoietic and excretory systems. As a result, there was a strict correlation between the concentrations of lead in the bones, and those in the liver and kidney, acting as tissues with the greatest importance for the diagnosis of lead poisoning (Clausen et al., 1982; Fisher et al., 2006).

The main reasons for such greatly increased lead concentration in the bones of mallards, according to Mateo et al. (2001), are the elevated needs of calcium and mineral components required for the activation of bone metabolism, especially in the case of restricted and grown for experimental purposes younger subjects.

Conclusions

The oral exposure to lead shot pellets # 3, leads to significant changes in certain haematological and biochemical parameters, manifested with anemia and metabolic changes. The observed toxicological effects are reflecting on the hematopoietic, excretory and musculoskeletal systems, generating repeatedly elevated levels in the soft tissues and in the bones.

Acknowledgements

These investigations were supported by project 13/19.01.2016 at University of Forestry, Sofia, Bulgaria

References

1. Beyer W. N., J. W. Spann, L. Sileo, J. C. Franson. (1988). *Lead poisoning in six captive avian species*. Archives of Environmental Contamination and Toxicology 17, 1988, 121–130.
2. Binkowski, Ł.J., Stawarz, R., Zakrzewski, M. (2013b). *Concentrations of cadmium, copper and zinc in tissues of Mallard and Coot from southern Poland*. Journal of Environmental Science and Health Part B 48, 410–415.
3. Clausen, B., Elvestad, K. and Karlog, O. (1982). *Lead Burden in Mute Swans from Denmark*. Nordisk Veterinaermedicin, 34, 83–91.
4. Del Bono, G., G. Braca. (1974). *Lead poisoning in domestic and wild ducks*. Avian Pathology, 2(3), 1974, 195–209.

5. De Francisco, N., J. D. Ruiz Troya, and E. I. Aguera. (2003). *Lead and lead toxicity in domestic and free living birds*. Avian Pathology 32:313.
6. Di Giulio R. T., and P. F. Scanlon. (1984). *Effects of cadmium and lead ingestion on tissue concentrations of cadmium, lead, copper and zinc in mallard ducks*. Sci. Total Environ. 39: 103–110.
7. Fisher, I.J., D.J. Pain, and V.G. Thomas. (2006). A review of lead poisoning from ammunition sources in terrestrial birds. Biological Conservation 131(3):421–432.
8. Friend, M. (1987). *Lead poisoning*. In M. Friend (Ed.), Field Guide to Wildlife Diseases, Vol. 1, pp. 175–189). Washington D.C.: US Department of the Interior, Fish and Wildlife Service.
9. Hutařová, Z., Forejtek, P., Večerek, V., Čelechovská, O., Svobodová, Z. (2015). *Mallards (Anas platyrhynchos) – a risk to human health from exposure to lead shots contaminating the environment*. Slovenian Veterinary Research, 2015, vol. 52, No 3, pp. 149–154.
10. Jeng S. L., Lee S. J., Liu Y. F., Yang S. C., Liou P. P. (1997). *Effect of lead ingestion on concentrations of lead in tissues and eggs of laying Tsaiya ducks in Taiwan*. 16 (1): 13–16.
11. Jordan, J. S., and F. C. Bellrose. (1951). *Lead poisoning in wild waterfowl*. Biological Notes, Urbana No. 26:1–27.
12. Kalisińska E, Salicki W, Myslek P. Using the Mallard to biomonitor heavy metal contamination of wetlands in north-western Poland. Sci Total Environ 2004; 320: 145–61.
13. Kamil, K. A., R. Kartasudjana, S. Iskandar and D. Latipudin. (2012). *Effect of Phytate in Diet and Lead in Drinking Water on Blood Mineral and Growth of Ducks*. Lucrări Științifice – Seria Zootehnie, vol. 58: 183–187.
14. Mateo, R., R., A.J. Green, C.W. Jeske, V. Urios, and C. Gerique. (2001). *Lead poisoning in the globally threatened marbled teal and white-headed duck in Spain*. Environmental Toxicology Chemistry 20(12):2860–2868.
15. Mateo, R. (2009). *Lead poisoning in wild birds in Europe and the regulations adopted by different countries*. In R. T. Watson, M. Fuller, M. Pokras, and W. G. Hunt (Eds.). Ingestion of Lead from Spent Ammunition: Implications for Wildlife and Humans. The Peregrine Fund, Boise, Idaho, USA. DOI 10.4080/ilsa.2009.0107.
16. Pain, D. J., I. J. Fisher, and V. G. Thomas. (2009). *A global update of lead poisoning in terrestrial birds from ammunition sources*. In Ingestion of Lead from Spent Ammunition: Implications for Wildlife and Humans (R. T. Watson, M. Fuller, M. Pokras, and W. G. Hunt, Editors). The Peregrine Fund, Boise, ID, USA. pp. 99–118.
17. Sanderson, G. C., and F. C. Bellrose. (1986). *A review of the problem of lead poisoning in waterfowl*. Illinois Natural History Survey Special Publication:1–34.
18. Szymczyk, K., Zalewski, K. (2003). *Copper, zinc, lead and cadmium content in liver and muscles of Mallards (Anas platyrhynchos) and other hunting fowl species in Warmia and Mazury in 1999-2000*. Polish Journal of Environmental Studies 12, 381–386.